

A new approach to iliac bone histomorphometry: implications for biomechanics and cell biology

A. Michael Parfitt

J Clin Invest. 2014;124(1):70-71. <https://doi.org/10.1172/JCI73843>.

Hindsight

I devised a method for obtaining information on cancellous bone structure from iliac bone histomorphometry that led to the demonstration that architecture is an important component of bone strength and bone fragility. Furthermore, this method contributed to the recognition of the importance of changes in osteoclast and osteocyte apoptosis in response to estrogen deficiency and replacement.

Find the latest version:

<https://jci.me/73843/pdf>





A new approach to iliac bone histomorphometry: implications for biomechanics and cell biology

A. Michael Parfitt

Division of Endocrinology and Metabolism, Center for Osteoporosis and Metabolic Bone Diseases,
University of Arkansas for Medical Sciences, Little Rock, Arkansas, USA.

I devised a method for obtaining information on cancellous bone structure from iliac bone histomorphometry that led to the demonstration that architecture is an important component of bone strength and bone fragility. Furthermore, this method contributed to the recognition of the importance of changes in osteoclast and osteocyte apoptosis in response to estrogen deficiency and replacement.

Loss of bone is a universal consequence of aging, from which no subset of the human species is exempt. Age-related bone loss can be demonstrated even in prehistoric populations. The magnitude of age-related cortical bone loss is easily measured on simple radiographs of the hands, but until approximately 25 years ago the magnitude of age-related cancellous bone loss could be measured only by histologic examination, either at autopsy or in iliac biopsy specimens. Cancellous bone has a complex three-dimensional structure that is similar in appearance to a honeycomb or a sponge. Until my 1983 paper (1), the only measurement made on clinical biopsy samples was the proportion of space occupied by bone, which is usually referred to in the clinical literature as cancellous (or trabecular) bone volume and in the biomechanical literature as bone volume fraction. Basing my research on earlier work by Robert Schenk (2, 3), I showed that with minimal expenditure of time, one could obtain additional structural indices of both clinical and scientific interest that only required calibration of an eyepiece graticule with a stage micrometer, and this could be used to determine absolute values of thickness, surface, and separation. The calculations were based on a parallel plate model of cancellous bone, which although extremely oversimplified, was a great improvement compared to ignoring structure altogether. This method enabled a rough description of the age-related transformation of trabeculae from plates to rods.

The most obvious implication of this work was biomechanical – the relationship between bone structure and bone strength. Patients with vertebral fracture had about 30% fewer plates in a cubic millimeter of cancellous bone tissue than expected, based on the values predicted from the linear regression analysis of the relationship between plate number and age in healthy subjects. Furthermore, plate number more clearly distinguished between subjects with and without vertebral fracture than trabecular bone volume. This was true for both sexes, although the deficit in bone thickness was greater in men than in women. In contrast, patients with hip fracture had a relative deficit in plate thickness that was greater than the deficit in plate number. As observed for patients with vertebral fracture, this deficit was greater in men than in women. The notion that there were differences as well as similarities in the pathogenesis of the two fracture types was proposed by Riggs and Melton in the same year, based on quite different reasoning (4).

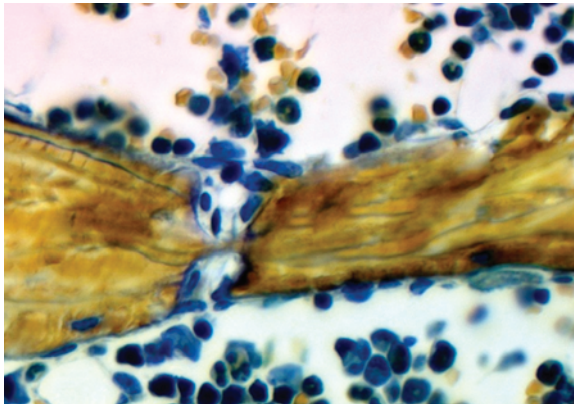
My colleague Michael Kleerekoper used data from our laboratory to show that patients with nontraumatic vertebral compression fracture had markedly fewer plates than healthy control subjects of similar age, matched for total amount of cancellous bone (5). Due to the method of selection, the patients had thicker trabeculae, which surprisingly had not restored vertebral compression strength. Later we collaborated with Lee Feldkamp, who examined cylindrical biopsy specimens with microcomputed tomography. This technique produced an index of three-dimensional connectivity that revealed greater differences between the groups (6).

This led to an explosion of new methods for examining the three-dimensional structure of bone, with progressively greater resolution, that could be applied to patients without biopsy. Together these methodologies confirmed and extended our conclusions. Bone architecture had become a major component of bone quality, a convenient term for all non-mass factors that contribute to fracture risk (7).

Trabecular plate number was significantly lower in healthy postmenopausal women than in healthy premenopausal women; however, the difference in trabecular thickness was much smaller, and in our subjects was not statistically significant (1). In our cross-sectional study, we could not distinguish between the effects of age and the effects of menopause. At this time, it was already known that after oophorectomy, which causes abrupt rather than gradual estrogen deficiency, vertebral cancellous bone mass declines rather rapidly (8). Our data suggested that in the first few years after menopause, some structural elements of cancellous bone are completely removed, and those remaining gradually become thinner, an effect most likely due to a defect in osteoblast function. This sequence could only be initiated if the earliest effect of estrogen deficiency was the perforation of trabecular plates, which could only occur as a result of increased depth of osteoclastic resorption (Figure 1). At first, I postulated the presence of “killer” osteoclasts that removed bone more voraciously as the underlying cause of increased resorption depth. I soon realized that increased depth was most likely due to resorption lasting longer, which led to a focus on increased osteoclast life span. Apoptosis of osteoclasts was first demonstrated by David Hughes (9), and consideration of this process led to formulation of a new model of bone resorption control (10). My current colleagues at the University of Arkansas for Medical Sciences have demonstrated that osteoclast apoptosis

Conflict of interest: The author has declared that no conflict of interest exists.

Citation for this article: *J Clin Invest.* 2014; 124(1):70–71. doi:10.1172/JCI73843.

**Figure 1**

Estrogens attenuate osteoclast generation and life span via cell-autonomous actions mediated by estrogen receptor α . Loss of these actions is sufficient for loss of bone in the cancellous compartment, in which complete perforation of trabeculae by osteoclastic resorption precludes subsequent refilling of the cavities by the bone-forming osteoblasts. The direction of BMU advance is not shown because of the section plane. Image courtesy of Robert Weinstein and reproduced with permission from Springer (20).

is postponed by estrogen deficiency and that osteoclast life span is restored to normal by estrogen replacement via cell-autonomous effects, which are mediated by estrogen receptor α (11).

A final implication of this work that is subtler and less well established concerns more recent knowledge of cancellous bone remodeling and the role of osteocytes in this process (12). Osteoclasts work not in isolation but in tandem with osteoblasts in a temporary structure referred to as the bone multicellular unit (BMU), the function of which is replacement of effete bone by new bone (13). Osteoclasts travel not perpendicular to the surface but at the front end of a BMU, which excavates a trench across the surface of cancellous bone (14). Consequently, in order to accomplish plate perforation, the BMU must change direction from a trajectory that is parallel to the surface to one that is at a downward angle. The direction of BMU advance can only be controlled by osteocytes (15). BMUs that repair fatigue microdamage follow signals from dying osteocytes (16). Osteocyte death increases with age in central interstitial bone (17). In a cross-sectional study, we could not

find an effect of menopause, but ovariectomy in rats increases osteocyte apoptosis, which is prevented by estrogen replacement (18). BMUs that follow signals from dying osteocytes in interstitial bone would likely lead to plate perforation, particularly if the plate was simultaneously attacked from both sides (Figure 1 and ref. 19).

Acknowledgments

I thank Stavros Manolagas, Robert Weinstein, and Leah Elrod for their assistance.

Address correspondence to: A. Michael Parfitt, 4301 West Markham, #587, Little Rock, Arkansas 72205-7199, USA. Phone: 501.686.5130; Fax: 501.686.8148; E-mail: parfittalwynn@uams.edu.

1. Parfitt AM, Mathews CH, Villanueva AR, Kleerekoper M, Frame B, Rao DS. Relationships between surface, volume, and thickness of iliac trabecular bone in aging and in osteoporosis. Implications for the microanatomic and cellular mechanisms of bone loss. *J Clin Invest.* 1983;72(4):1396-1409.
2. Merz WA, Schenk RK. Quantitative structural analysis of human cancellous bone. *Acta Anat.* 1970; 75:54-66.
3. Schenk RK. Trabecular bone volume in iliac crest biopsies. In ZFG Jaworski, ed. *Proceedings of the First Workshop on Bone Morphometry.* Ottawa, Ontario, Canada: University of Ottawa Press; 1976:97-99.

4. Riggs BL, Melton LJ 3rd. Evidence for two distinct syndromes of involutional osteoporosis. *Am J Med.* 1983;75(6):899-901.
5. Kleerekoper M, Villanueva AR, Stanciu J, Rao DS, Parfitt AM. The role of three-dimensional trabecular microstructure in the pathogenesis of vertebral compression fractures. *Calcif Tissue Int.* 1985;37(6):594-597.
6. Feldkamp LA, Goldstein SA, Parfitt AM, Jesion G, Kleerekoper M. The direct examination of three-dimensional bone architecture in vitro by computed tomography. *J Bone Miner Res.* 1989;4(1):3-11.
7. Heaney RP. Is there a role for bone quality in fragility fractures? *Calcif Tissue Int.* 1993;53(suppl 1):S3-S5.
8. Genant HK, Cann CE, Ettinger B, Gordan GS. Quantitative computed tomography of vertebral spongiosa: a sensitive method for detecting early bone loss after oophorectomy. *Ann Intern Med.* 1982;97(5):699-705.
9. Hughes DE, et al. Bisphosphonates promote apoptosis in murine osteoclasts in vitro and in vivo. *J Bone Miner Res.* 1995;10(10):1478-1487.
10. Parfitt AM, Mundy GR, Roodman GD, Hughes DE, Boyce B. A new model for the regulation of bone resorption, with particular reference to the effects of bisphosphonates. *J Bone Miner Res.* 1996;11(2):150-159.
11. Manolagas SC, O'Brien CA, Almeida M. The role of estrogen and androgen receptors in bone health and disease [published online ahead of print September 17, 2013]. *Nat Rev Endocrinol.* doi:10.1038/nrendo.2013.179.
12. Manolagas SC, Parfitt AM. For whom the bell tolls: Distress signals from long-lived osteocytes and the pathogenesis of metabolic bone diseases. *Bone.* 2013;54(2):272-278.
13. Parfitt AM. New concepts of bone remodeling: a unified spatial and temporal model with physiological and pathophysiological implications. In: Agarwal SC, Stout SD, eds. *Bone Loss and Osteoporosis: An Anthropological Perspective.* New York, New York, USA: Kluwer Academic/Plenum Publishers; 2003:3-17.
14. Parfitt AM. Osteonal and hemi-osteonal remodeling: The spatial and temporal framework for signal traffic in adult human bone. *J Cellular Biochem.* 1994;55(3):273-286.
15. Bonewald LF. The amazing osteocyte. *J Bone Miner Res.* 2011;26(2):229-238.
16. Kennedy OD, Herman BC, Laudier DM, Majeska RJ, Sun HB, Schaffler MB. Activation of resorption in fatigue-loaded bone involves both apoptosis and active pro-osteoclastogenic signaling by distinct osteocyte populations. *Bone.* 2012;50(5):1115-1122.
17. Qiu S, Palnitkar S, Rao DS, Parfitt AM. Age and distance from the surface but not menopause reduce osteocyte viability in human cancellous bone. *Bone.* 2002;31(2):313-318.
18. Tomkinson A, Gevers EF, Wit JM, Reeve J, Noble BS. The role of estrogen in the control of rat osteocyte apoptosis. *J Bone Miner Res.* 1998;8(8):1243-1250.
19. Reeve J. A stochastic analysis of iliac trabecular bone dynamics. *Clin Orthop Relat Res.* 1986;(213):264-278.
20. Weinstein RS. Understanding bone histomorphometry: sampling, evaluation, and interpretation. In: Orwoll ES, ed. *Atlas of Osteoporosis.* 3rd ed. Philadelphia, Pennsylvania, USA: Springer; 2009:13-19.